

Acute pancreatitis during liver hydatidosis: treatment with ERCP and endoscopic sphincterotomy



Ann. Ital. Chir., 2005; 76: 491-494

Carmelo Sciumè, Girolamo Geraci, Franco Pisello, Tiziana Facella, Roberto Vaglica, Giuseppe Modica.

Università degli Studi di Palermo, Sezione di Chirurgia Generale ad Indirizzo Toracico, Azienda Ospedaliera, Universitaria Policlinico "Paolo Giaccone", Dipartimento di Chirurgia Generale, d'Urgenza e dei Trapianti d'Organo, Direttore: Prof. G. Modica.

Acute pancreatitis during liver hydatidosis: Treatment with ERCP and endoscopic sphincterotomy

INTRODUCTION: *The Authors report on a case of a young woman who developed acute pancreatitis when affected by liver hydatidosis, successfully treated with endoscopic retrograde cholangiopancreatography (ERCP) and endoscopic sphincterotomy.*

METHODS: *An endoscopic sphincterotomy was performed, with extraction of multiple hydatid membranes.*

OBSERVATIONS: *Laboratory values returned to normal within 36 hours of the sphincterotomy. The patient was dismissed with oral therapy (Albendazole 400 mg bis in die for 4 months) and antibodies to Echinococcus were not detectable 1 month later. One year later, at ultrasound and CT the hydatid cyst was regressed and patient was still without symptoms.*

CONCLUSIONS: *Hydatid membranes in the biliary tract should be considered as a potential cause of pancreatitis in patients with hydatidosis, even if it is a rare complication, caused by the obstruction of the distal part of common bile duct by fragments of hydatid membranes, scolices or daughter cysts. ERCP may be resolute, but surgery remains the treatment of choice for treatment of liver hydatid cysts.*

KEY WORDS: Acute pancreatitis, Complications, ERCP, Liver hydatidosis (echinococcosis).

Hydatidosis is a zoonosis that is generally caused by infection with tapeworms (*Echinococcus granulosus*). When the parasite eggs are ingested by human beings, the infective forms penetrate the intestinal wall and reach the liver via the portal circulation. In some cases, the hydatid cyst subsequently ruptures into the biliary tract¹.

Patients who have pancreatitis caused by hydatid membranes in the biliary tract have been treated, generally, by surgery.

We have encountered one case of acute pancreatitis caused by the presence of hydatid membranes in the biliary tract and in which the problem was resolved by endoscopic sphincterotomy.

Case report

A 18-year-old female was referred to our hospital with

epigastric pain radiating to the back, jaundice, fever, nausea and emesis over a period of 12 hours. There was no history of drug or ethanol abuse. The patient had a history of hepatic hydatidosis (VII-VIII segments, diameter about 6 cm). Epigastric tenderness was found on physical examination. The most relevant laboratory results are summarized in Table I.

An abdominal US and CT confirmed a 6 cm diameter hydatid cyst in the right lobe with dilatation of biliary tract (12 mm) and irregular echogenic material in the lumen; the pancreas was enlarged and there were several peripancreatic fluid accumulations together with a little left pleural effusion.

ERCP (Fig. 1) revealed a normal main duodenal papilla with dilated common bile duct. On cholangiography, a dilated biliary tract (15 mm) containing multiple filling defects, mobile and with irregular morphology was seen. The pancreatogram was normal. An endoscopic sphincterotomy was performed and multiple hydatid membranes were extracted with a balloon catheter and Dormia basket (flat, green-yellowish membranes were extracted). The patient progressed satisfactorily, labora-

Pervenuto in Redazione Settembre 2004. Accettato per la pubblicazione Febbraio 2005.

Per la corrispondenza: Prof. Carmelo Sciumè, Via Eduardo Carapelle 12, 90129 Palermo (e-mail: carmesci@hotmail.com - girgera@tin.it).

TABLE I – Laboratory results

Parameter	Admission	Post-ERCP	Dismission	Normal range
Amylase	1250	200	130	12-125 IU/L
Lipase	3220	1125	220	1-190 IU/L
Alanine aminotransferase	150	100	39	5-37 IU/L
Aspartate aminotransferase	230	122	53	5-40 IU/L
Gamma-Glutamyl transpeptidase	360	154	48	5-50 IU/L
Alkaline phosphatase	481	218	223	98-279 IU/L
Bilirubin	9.7	4.1	1.0	0.1-0.6 mg/dL
Leukocytes	18630	7300	5420	4.800-10.800/muL

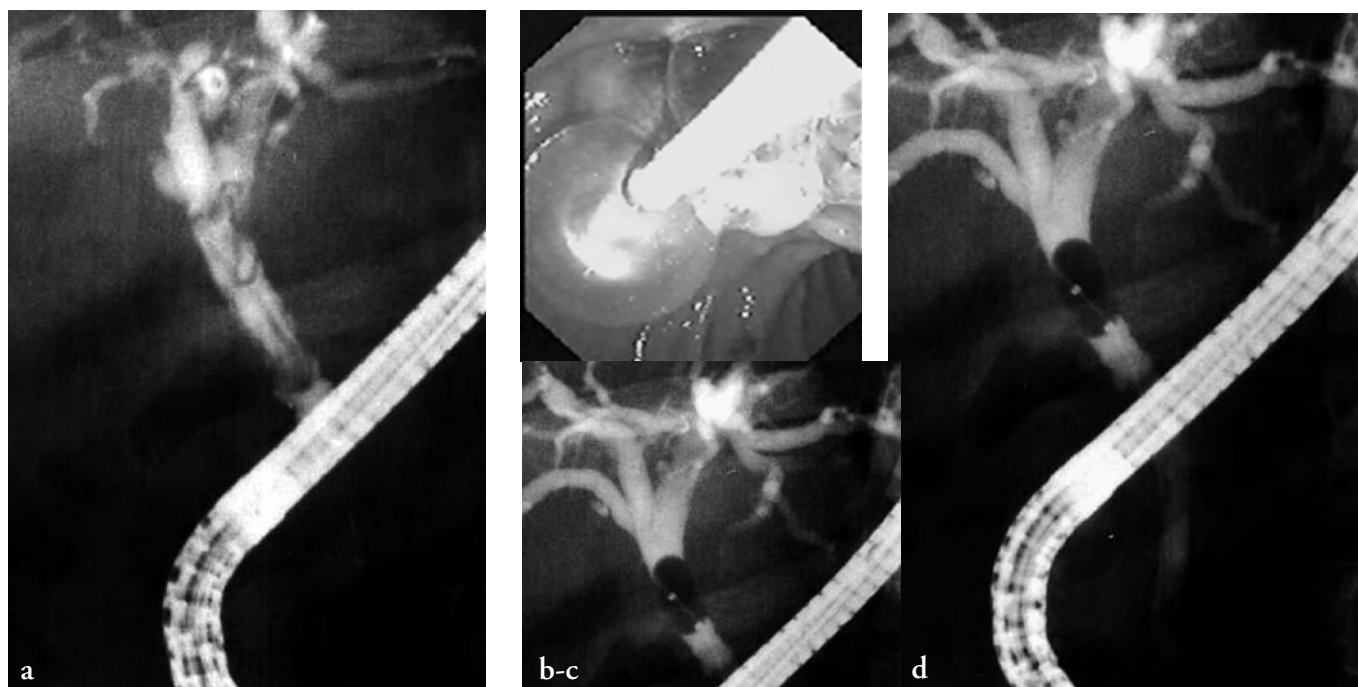


Fig. 1: a) Dilated biliary tract (15 mm) containing multiple filling defects, mobile and with irregular morphology; b-c-d) Extraction of multiple hydatid membranes.

tory values returned to normal within 36 hours of the sphincterotomy. The patient was dismissed with oral therapy (Albendazole 400 mg bis in die for 4 months) and antibodies to *Echinococcus* were not detectable 1 month later. One year later, the hydatid cyst was regressed and patient was still without symptoms.

Discussion

Hepatic hydatidosis is a common disease in countries where the livestock are guarded by dogs¹. It is endemic in Italy, with an annual incidence of 50-200 cases per 100000 inhabitants (Sardinia 14.32 cases per 100000, Sicily 4.5 casi / 100000)². Spontaneous rupture of the hepatic hydatid cyst into the biliary tract occurs in 3.2% to 37% of the cases^{1,3}, frank perfora-

tion in 3.2-17% and occult rupture in 10-37%¹. Intrabiliary rupture of echinococcal cyst has been classified as either frank perforation with overt passage of hydatid material into the biliary tract or as occult leakage with signs of suppuration alone¹ into three types: (a) contained rupture, referring to perforation of the true parasitic cystic wall within the host-derived pericyst, (b) communicating rupture, describing evacuation of cyst contents via anatomical diversion structures and (c) direct rupture (e.g. spilling of cyst material by a non-physiological route into preformed body cavities or adjacent hollow viscus)¹. Rupture of the cyst into the biliary tract is associated with abdominal pain in 92% to 100% of the cases, with jaundice in 79% to 100%, fever in 60% to 93%, and cholangitis in 20% to 67%¹. Less often, urticaria, anaphylactic shock, obstructive jaundice, secondary infection of the cyst, or dissemination to other

organs may occur. However, the association with acute pancreatitis has been reported only rarely⁴⁻⁷.

In the patient described above, the diagnosis of pancreatitis was confirmed on the basis of marked increases in the concentrations of serum amylase and lipase (in addition to the US and CT evidence). The concomitant diagnosis of hydatidosis of the biliary tract was made based on the positive serological tests for hydatidosis together with visualization of the hydatid membranes during sphincterotomy⁸. Contrary to reports of similar cases, our patient had not been episodes of recurrent acute pancreatitis (would appear to be a late complication of hydatidosis)⁹.

The efficacy and safety of endoscopic sphincterotomy and membrane extraction for the treatment of hydatid cysts with rupture into the biliary tract is well established^{9,10,18}, even if the successful use of this technique in the treatment of pancreatitis associated with hepatic hydatidosis has been described previously in only five reports¹¹⁻¹⁵.

Conclusions

In conclusion, one case of acute pancreatitis clearly related to rupture of hydatid cyst into the biliary tract have been presented. Hydatid membranes in the biliary tract should be considered as a potential cause of pancreatitis in patients with hydatidosis. This possibility should be taken into consideration in patients presenting with pancreatitis and hepatic hydatid cyst¹⁶, even if it is a rare complication, caused by the obstruction of the distal part of common bile duct by fragments of hydatid membranes, scolices or daughter cysts.

ERCP may be resolutive, but surgery remains the treatment of choice for treatment of liver hydatid cysts^{17,19}.

Riassunto

INTRODUZIONE: Viene descritto il caso di una giovane donna portatrice di cisti epatica da echinococco che ha sviluppato un episodio di pancreatite acuta, trattata con successo mediante una ERCP con sfinterotomia endoscopica.

METODI: È stata eseguita una ERCP con sfinterotomia endoscopica (SE) ed estrazione di multiple caratteristiche membrane idatidee.

OSSERVAZIONI: I test di laboratorio sono andati incontro a normalizzazione a 36 ore dalla sfinterotomia. La paziente è stata quindi dimessa con terapia medica (Albendazolo 400 mg, 2 compresse al giorno per 4 mesi) e ad 1 mese il titolo anticorpale non è stato determinabile. Un anno dopo, la cisti epatica non era più valutabile all'imaging e la paziente è rimasta asintomatica.

CONCLUSIONI: Membrane idatidee nella via biliare possono essere considerate causa potenziale di pancreatite acuta da ostruzione. In tali casi, la ERCP può essere

risolutiva, ma la chirurgia rimane il trattamento di scelta per l'idatidosi epatica.

References

- 1) Sherlock S, Dooley J: *Diseases of the liver and biliary system*. 10th ed. Oxford: Blackwell Scientific Publ., 1997.
- 2) Cirenei A, Bertoldi I: *Evolution of surgery for liver hydatidosis from 1950 to today: Analysis of a personal experience*. World J Surg, 2001; 25(1):87-92.
- 3) Perdomo R, Alvarez C, Monti J, Ferriera C, Chiesa A, Carbò A, Alvez R, Grauert R, Stern D, Carmona C, Yarzabal L: *Principles of the surgical approach in human liver cystic echinococcosis*. Acta Tropica, 1997; 64:109-22.
- 4) Mestiri S, Hadj Salah M, Laarif R, Kehila M: *Kyste hydatique du foie ouvert dans les voies biliaires et pancreatite aigue. Problemes etio-pathogeniques a propos de 3 cas*. Med Chir Dig, 1982; 11:197-99.
- 5) Aydin A, Ersoz G, Tekesin O, Menten A: *Hydatid acute pancreatitis: A rare complication of hydatid liver disease. Report of two cases*. Eur J Gastroenterol Hepatol, 1997; 9:211-14.
- 6) Daali M, Fakir Y, Hssaida R, Hajji A, Had A: *Les kistes hydatiques du foie rompus dans les voies biliaires. A propos de 64 cas*. Ann Chir, 2001; 126:242-45.
- 7) Wong LS, Braghirolli-Neto O, Xu M, Buckels JAC, Mirza DF: *Hydatid liver disease as a cause of recurrent pancreatitis*. J R Coll Surg Edinb 1999; 44:407-9.
- 8) Parenti DM, Steinberg W, Kang P: *Infectious causes of acute pancreatitis*. Pancreas, 1996; 13:356-71.
- 9) Spiliadis C, Georgopoulos S, Dailianas A, Konstantinidis A, Rimikis M, Skandalis N: *The use of ERCP in the study of patients with hepatic echinococcosis before and after surgical intervention*. Gastrointest Endosc, 1996; 43:575-79.
- 10) Vignote ML, Mino G, de la Mata M, de Dios JF, Gomez F: *Endoscopic sphincterotomy in hepatic hydatid disease open to the biliary tree*. Br J Surg, 1990; 77:30-31.
- 11) Brannath J, Bartscher U: *Echinokokkose der Gallenwege als seltene Ursache eines Verschlussikterus*. Dtsch Med Wochenschr, 1987; 112:16-19.
- 12) Medina E, Orti E, Canelles P, Calvo MA, Molina E: *Quiste hidatidico hepatico complicado y pancreatitis aguda. Valor de la CPRE y tratamiento con esfinterotomia endoscopica*. Rev Esp Enferm Dig, 1990; 78:315-18.
- 13) Al-Toma AA, Vermeijden RJ, van de Wiel A: *Acute pancreatitis complicating intrabiliary rupture of liver hydatid cyst*. Eur J Int Med, 2004; 15:65-67.
- 14) Saez-Royuela F, Yuguero L, Lopez-Morante A, Perez-Alvarez JC, Martin-Lorente JL, Ojeda C: *Acute pancreatitis caused by hydatid membranes in the biliary tract: Treatment with endoscopic sphincterotomy*. Gastrointest Endosc, 1999; 49(6):793-96.
- 15) Salgarello G, Bruzzone P, Salgarello T, Giannatempo GM, Alcaro G, De Vivo D: *Invasione delle vie biliari da rottura di cisti idatidea e pancreatite acuta*. G Chir 1989; 10:259-61.
- 16) Aydin A, Ersoz G, Tekesin O, Menten A: *Hydatid acute pancreatitis: a rare complication of hydatid liver disease. Report of two cases*. Eur J Gastroenterol Hepatol, 1997; 9:211-14.
- 17) Alonso Casado O, Moreno Gonzalez E, Loinaz Seguro C,

Gimeno Calvo A, Gonzalez Pinto I, Perez Saborido B, Paseiro Crespo G, Ortiz Johansson C: *Results of 22 years of experience in radical surgical treatment of hepatic hydatid cysts*. Hepatogastroent, 2001; 48:235-43.

18) Sciumè C, Geraci G, Pisello F, Li Volsi F, Facella T, Modica

G: *Treatment of complications of hepatic hydatid disease by ERCP: our experience*. Ann Ital Chir (in press).

19) Sciumè C, Geraci G, Pisello F, Li Volsi F, Facella T, Modica G: *Il trattamento chirurgico dell'idatidiosi epatica: nostra esperienza e considerazioni diagnostico-terapeutiche*. Ann Ital Chir (in press)..

Commento

Commentary

Prof. MARINO CAGETTI
Ordinario di Chirurgia Generale
Università di Cagliari

La segnalazione è incentrata su di un episodio di pancreatite da ostacolato deflusso del Wirsung per la presenza di membrane idatidee nella V.B.P., secondaria a rottura di una cisti epatica nelle Vie Biliari. La condizione è stata favorevolmente risolta mediante disostruzione attuata per via endoscopica (ERCP).

La segnalazione ha interesse anche per la coincidenza di numerosi fortunati eventi che hanno portato alla guarigione spontanea della cisti. La giovane età della paziente (18 anni) con fegato soffice, la verosimile giovane età della cisti a pericistio sottile, la rottura e completo svuotamento del materiale idatideo in un dotto biliare di calibro adeguato che è stato possibile rimuovere per via endoscopica, la mancata infezione e la spontanea elisione del cavo.

Qualora un ulteriore controllo a distanza, mediante TC spirale, dimostrasse la scomparsa della cisti, darebbe conferma della rara fortunata possibilità di una guarigione spontanea.

Ritengo, tuttavia, che di regola non si possa fare affidamento sulla coincidenza di tanti favorevoli fattori e, in presenza di una cisti di 6 cm, la condotta corretta comporti l'indicazione ad un intervento chirurgico possibilmente radicale (pericistectomia).

Only few cases of acute pancreatitis, as a complication of ruptured liver hydatid cyst, have been described.

This case is about the recovery from a secondary acute pancreatitis caused by the rupture of a liver hydatid cyst into the biliary tract obstruction of the Wirsung by hydatid membranes. The pancreatitis was treated successfully by endoscopic removal of membrane fragments from the obstructed biliary tract.

It is important to highlight some concomitant events which led to spontaneous recovery of the cyst: the patient is a young woman (18 year old), with soft liver; the young hydatid cyst had thin pericyst; the burst of the cyst and the complete emptying of it into a biliary tract of suitable dimension.

Another favourable event was the spontaneous elision of the cyst cavity without infection. If the spiral CT, during future follow-up (2 years), showed the disappearance of the cyst, the rare lucky possibility of its spontaneous recovery would be confirmed.

However, from our experience, we cannot count on such favourable events for a 6 cm hydatid cyst, We would strongly recommend, whenever possible, as a correct therapeutic choice, radical surgery (pericystectomy).

Surgery remains the treatment of choice for the management of hydatid cyst.