

# Laparoscopic Heller-Dor for primary esophageal achalasia

## Outcomes in 173 patients



Ann. Ital. Chir., 2013 84: 515-519  
pii: S0003469X13019490

Riccardo Rosati<sup>\*/\*\*</sup>, Uberto Fumagalli Romario<sup>\*</sup>, Martina Ceolin<sup>\*</sup>, Simonetta Massaron<sup>\*</sup>,  
Alberto Peracchia<sup>\*/\*\*</sup>

Istituto Clinico Humanitas IRCCS, Rozzano, Milan, Italy

<sup>\*</sup>Department of General and Minimally Invasive Surgery

<sup>\*\*</sup>Department of Surgery, University of Milan, Italy

### Laparoscopic Heller-Dor for primary esophagus achalasia. Outcome in 173 patients

**AIM:** *Laparoscopic Heller myotomy combined with anterior (Dor) fundoplication is the most widely-used surgical procedure for treating esophageal achalasia in Europe*

**MATERIAL OF STUDY:** *From November 1992 through May 2010 we performed laparoscopic Heller-Dor on 173 patients*

**RESULTS:** *Conversion to laparotomy was required in three cases (1.7%) at the beginning of the experience (for mucosal perforation which was the most frequent intraoperative complication, managed laparoscopically with the increasing experience. Five (2.9%) cases had minor postoperative complications. Clinical results were satisfactory in 99.4% of cases. One patient (0.6%) had severe persistent dysphagia. Mean esophageal diameter decreased from 50 mm  $\pm$  12 (range 20-90) to 25 mm  $\pm$  7 (range 15-80). Lower esophageal sphincter pressure decreased from 32 mmHg (median, range 10-93) pre-operatively to 11 mmHg (median, range 5-21) at one year follow up and residual pressure from 12 mmHg (median, range 3-30) to 4 mmHg (median, range 1-8). Impedance and pH monitoring showed normal levels in 39/47 (83%) patients who agreed to testing.*

**CONCLUSION:** *The good outcomes of this experience, in part due to careful adherence to technical aspects of the operation, confirm that the laparoscopic Heller-Dor is the gold standard surgical treatment for esophageal achalasia*

**KEY WORDS:** Achalasia, Dor fundoplication, Laparoscopy, Heller myotomy

### Introduction

Laparoscopic Heller myotomy with Dor anterior antireflux fundoplication is widely used to treat stage I-III achalasia<sup>1-3</sup>. The laparoscopic approach has been shown to be safe and effective, offering the same functional results compared to laparotomy<sup>4-8</sup>, but with all the advantages of minimally-invasive surgery. This paper presents long-term results Heller-Dor in a consecutive series

of patients with esophageal achalasia, treated in our centre from 1992 and with one year follow-up. Based on this experience will discuss of the operation details which contribute decisively to long-term resolution of dysphagia with minimal incidence of postoperative gastroesophageal reflux.

### Materials and Methods

Between November 1992 and May 2010, 173 patients (91 men, 82 women) of median age of 44 years (range 9-86) underwent laparoscopic Heller-Dor for esophageal achalasia. Dysphagia was mild in 10 (5.8%) patients, moderate in 68 (39.3%) and severe in 95 (54.9%). Based

Correspondence to: Riccardo Rosati, MD FACS, Department of General and Minimally Invasive Surgery, Istituto Clinico Humanitas IRCCS, Via Manzoni 56, 20089 Rozzano (MI), Italy (e-mail: riccardo.rosati@humanitas.it)

on x-ray findings, 13 patients had stage I achalasia (esophageal diameter  $<4$  cm), 127 had stage II (esophageal diameter  $\leq 4 < 6$  cm), 20 had stage III ( $\geq 6$  cm) and 13 had stage IV (dolichomegasophagus). The stage IV patients underwent Heller-Dor as a conservative alternative to esophagectomy. Preoperative work-up included barium swallow, esophagoscopy and esophageal manometry in all patients. Twenty-six patients (15%) had undergone a median of 1 (range 1-4) endoscopic dilations before surgery, 8 (4.6%) had received a median of 1 (range 1-4) endoscopic injection of botuline toxin.

All laparoscopic procedures were performed under general anesthesia and endoscopic control as previously described<sup>1</sup>. On the first postoperative day a soft diet was assumed after gastrographic swallow.

Follow-up was based on clinical assessment and barium swallow one month after surgery; clinical assessment endoscopy, barium swallow and manometry within a year; clinical examination yearly with objective examinations performed according to patient needs. Twenty-four-hour pH monitoring (impedance monitoring after September 2004) was offered to all patients at the same time as the endoscopy and manometry, but only 47 patients agreed to undergo the exam.

#### STATISTICAL ANALYSIS

The statistical analysis was carried out using Stat Software for Windows (StatSoft. Inc., Tulsa, USA). Descriptive statistics are expressed as medians with ranges and means with standard deviations. The Mann-Whitney U test was used to compare two independent groups of data.

#### Results

Mean esophageal diameter, as measured on barium swallow study, was  $50 \text{ mm} \pm 12$  (range 20-90). Median basal and residual lower esophageal sphincter (LES) pressure, respectively, at manometry were 32 mmHg (range 10-93) and 12 mmHg (range 3-30). Intraoperative complications were one (0.6%) splenic lesion treated by electrocautery and 30 (17.3%) cases of mucosal perforation (11 out of 30 patients underwent previous treatments for achalasia). In one case the tear was in the mediastinal esophagus, and in the other 29 cases was at the esophagogastric junction. Two gastro-esophageal perforations occurred when the anesthesiologist exerted inappropriate force on the nasogastric tube. The first two cases of mucosal perforation were converted to open surgery for repair, all the others were sutured laparoscopically. Laparotomy was also required in another case to overcome difficult exposure due to a hypertrophic left liver lobe. All three (1.7%) conversions occurred within the first 10 operations. For the 170 procedures completed laparoscopically, median operating time was 90 min (range 59-200 min).

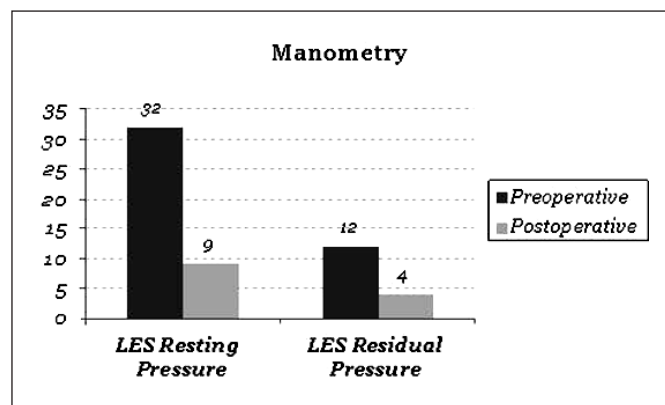


Fig. 1: Resting and residual LES pressure before and after surgery (one year follow up) in 72 patients who received laparoscopic Heller-Dor for esophageal achalasia.

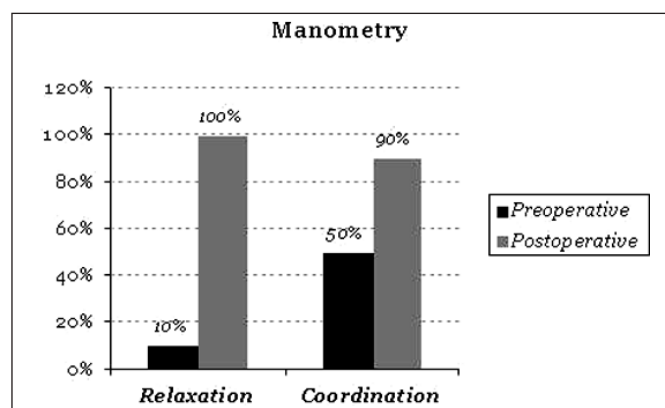


Fig. 2: Relaxation and coordination of LES pressure before and after surgery (one year follow up) in 72 patients who received laparoscopic Heller-Dor for esophageal achalasia.

There was no perioperative mortality. All sutured mucosal perforations healed without requiring the nasogastric tube to be placed for longer than usual (i.e. first 24 hrs). Postoperative complications occurred in five (2.9%) patients: minimal leak detect patients at gastrographin swallow in two (1.1%) (in whom gross intraoperative mucosal perforation was not evident), bleeding from acute gastric ulcer in one (0.6%), trocar-related hemoperitoneum in one (0.6%) and displacement of abdominal drainage in another (0.6%). The first three postoperative complications were treated conservatively, the other two required a second laparoscopy. Liquid intake in uncomplicated patients was possible on the first post surgical day. A soft diet was resumed a median of two days (range 2-16) after the operation. Median postoperative hospital stay was 3 days (range 3-19).

After a median follow-up of 50 months (range 12-180), clinical evaluation showed complete symptoms relief in 138 patients (79.8%), whereas 34 (19.6%) reported occa-

sional mild dysphagia; thus 172/173 (99.4%) patients had satisfactory outcomes.

One patient (0.6%) had severe persistent dysphagia caused by an incomplete myotomy and resolved by a pneumatic dilation.

Four (2.3%) patients had reflux symptoms; three of them (1.7%) required chronic proton pump inhibitor therapy. Esophageal diameter reduced from a mean of 50 mm  $\pm$  12 (range 20-90) to a mean of 25 mm  $\pm$  7 (range 15-80). Manometry was performed in 72 patients at one year follow up (other patients refused to perform the examination). In all cases LES reduced in comparison to preoperative levels (Figs. 1, 2). Basal LES reduced from a median of 32 mmHg (range 10-93) to 11 mmHg (range 5-21) ( $p < 0.01$ , Mann-Whitney U test) and residual pressure reduced from 12 mmHg (3-30) to 4 mmHg (1-8) ( $p < 0.01$ , Mann-Whitney U test).

Impedance pH monitoring was normal levels in 39/47 (83%) patients who agreed to testing. It was pathological for acid reflux (pH  $< 4$  for  $> 5\%$  of time) in 2 patients (4.2%) and for non-acid reflux in 6 patients (12.8%).

## Discussion

We performed open surgery Heller-Dor during the 1970s and 1980s, showing that it was a safe and durably effective procedure for esophageal achalasia<sup>8</sup> and we early adopted the laparoscopic operation at the beginning of the 1990s<sup>1</sup>. To increase the safety and reduce the difficulty of the laparoscopic procedure we soon introduced intraoperative endoscopy<sup>1</sup> and special myotomy scissors (Microfrance Medtronic, Sr. Aubin Le Monial, France)<sup>9</sup> which are a modified evolution of the Sugarbaker pericardiotomy scissors, with a smooth protected boot encasing the lower scissor blade which allows proper dissection of the submucosal plane and a clear cut of the muscle with than undamaged borders useful for a secure suture of the gastric fundus during fundoplication<sup>10</sup>. We believe that the success of the operation also depends on careful adherence to a number of technical procedures during the operation. Minimal esophageal dissection which is carried out just on its anterior surface between the diaphragmatic crura after minimal incision of the Leimer-Bertelli membrane. Thus, the anatomic attachments of the gastroesophageal junction are preserved: only the phrenogastric ligament may be divided to attain a floppy anterior wrap. The short gastric vessels should almost never be sectioned (in only two cases in the present series)<sup>5,11</sup>. Intraoperative endoscopy allows esophageal transillumination which is used to facilitate identification of the plane between the submucosa and circular muscle and makes it easier the identification of accidental mucosal perforation.

The proximal extension of the myotomy cranially is pushed for about 7 cm: an important rule to remember is that upper myotomy has to be extended until the esophageal

muscle is thick or until an inadvertent perforation can be repaired easily. Onto the cardia, it has to be extended for about 2 cm with a thorough division of the oblique fibers of the cardia. Failure to section all this muscle fibers is frequently responsible for persistent dysphagia after surgery<sup>11</sup>. We use a hook as the instrument of choice for dividing the distal muscle fibers. The changing direction of the fibers – circular in the esophagus to oblique in the cardia – is best visualized by esophagoscopic transillumination and mild distension of the cardia with smooth insufflation. The cardia is more richly endowed with blood vessels than the esophagus and bleeding can be pronounced: it must be controlled effectively but with great care since coagulation can cause immediate or delayed mucosal perforation. In previously treated patients (pneumatic dilatation or Bo-tox injection), fibrosis is often severe in this region, making it difficult to dissect between muscle and submucosa. After Bo-tox treatment, in particular, the muscle layers become strongly attached to a whitish fibrotic tissue that is particularly difficult to dissect. Eight of our 30 mucosal perforations occurred at this level.

All mucosal perforations were recognized and repaired intraoperatively, in 28 with laparoscopic suture, without clinical consequences, in 2 after conversion to open surgery at the very beginning of the experience. Two gastroesophageal perforations occurred when the anesthesiologist forcefully pushed on the nasogastric tube without waiting for the advice from the surgeon. We emphasize that maneuvers by the endoscopist or anesthesiologist should always be authorized by the surgeon and performed under visual control. When the mucosa is perforated, 5-0 absorbable sutures tied intracorporeally are sufficient to effect repair.

Addition of a Dor fundoplication to the myotomy provides additional protection to the esophageal mucosa, allowing early resumption of oral feeding and also helping to prevent scarring of the cut edges of the myotomy. In particular, the practice of fixing the cranial suture of the wrap on each side not only to the myotomy edges but also to the diaphragmatic crura helps to keep the edges of the myotomy apart and discourage the formation of scar tissue on the muscle.

The main reason for fundoplication after myotomy is to prevent reflux of gastric fluids into the esophagus<sup>12</sup>. However, there is no consensus regarding the need for fundoplication after myotomy for achalasia. There is also controversy regarding the type of fundoplication that should be performed<sup>12</sup>. In a previous paper on 79 patients referred to us after failed esophagomyotomy performed elsewhere, the problem was reflux esophagitis in 22.8% and persistent dysphagia following incomplete myotomy after Heller-Nissen in the remaining cases<sup>11</sup>. Even with a single episode of reflux, defective esophageal clearance in patients with achalasia means that gastric juice is in prolonged contact with the esophageal mucosa. To prevent reflux and the resulting esophagitis, some

authors advocate Nissen fundoplication<sup>13,14</sup>. However, a balance must be struck between addressing the dysphagia and preventing subsequent reflux: this boils down to constructing a non-obstructive but effective fundoplication. Fundoplication should not be necessary when a thoracoscopic myotomy is performed<sup>15</sup> because with this approach, hiatal attachments are only minimally damaged and iatrogenic reflux is rare (but the myotomy is more difficult and more often incomplete at the level of the lower part of the lower esophageal sphincter, so that postoperative dysphagia is more common)<sup>12</sup>. When a trans-abdominal Heller is performed, either laparoscopically or by open surgery, using optimal technique (minimal dissection of anterior esophagus, no circumferential dissection), a partial anterior wrap – such as the Dor fundoplication – is more than sufficient to prevent reflux in the great majority of cases<sup>16</sup>. Partial posterior fundoplications, such as the Toupet<sup>17</sup> or Nissen, require greater mobilization of the esophagogastric junction with circumferential dissection.

In our opinion, floppy Nissen should be reserved for patients with effective esophageal motility, and not for those with a primary motor disorder like achalasia<sup>14,18</sup>. An important result of the present series is that functional outcomes in terms of basal and resting pressures in the lower esophageal sphincter were similar to those of Dor et al in their open series published in 1962<sup>5</sup>. In conclusion, the good long-term clinical and functional results presented in this paper demonstrate the effectiveness, feasibility and safety of laparoscopic Heller myotomy combined with Dor fundoplication as primary treatment for achalasia; careful attention is paid to the technical details discussed above. The main advantages of the laparoscopic approach over the open procedure are reduced trauma and pain with shorter postoperative hospitalization. Laparoscopic Heller-Dor should be considered the first choice surgical option for the treatment of esophageal achalasia.

### Riassunto

**INTRODUZIONE:** L'intervento di Heller-Dor è la procedura chirurgica più utilizzata per il trattamento dell'acalasia esofagea in Europa.

**MATERIALE DELLO STUDIO:** Da novembre 1992 a maggio 2010, sono stati sottoposti ad intervento di Heller-Dor con approccio laparoscopico 173 pazienti.

**RISULTATI:** La conversione in chirurgia aperta si è resa necessaria in tre casi (1.7%) all'inizio dell'esperienza prevalentemente per perforazione mucosa che ha costituito la principale complicanza intraoperatoria trattata per via laparoscopica con l'aumentare dell'esperienza. Le complicanze postoperatorie, tutte minori, si sono osservate nel 2.9% dei casi (5/173). I risultati clinici sono stati soddisfacenti nel 99.4% dei pazienti. Un paziente (0.6%) ha manifestato una disfagia severa postoperatoria. Il dia-

metro medio dell'esofago si è ridotto da 50 mm ± 12 (media, range 20-90) a 25 mm ± 7 (media, range 15-80). La pressione basale dello sfintere esofageo inferiore si è ridotta da 32 mmHg (mediana, range 10-93) preoperatoriamente ad 11 mmHg (mediana, range 5-21) ad un anno dall'intervento e la pressione residua da 12 mmHg (mediana, range 3-30) a 4 mmHg (mediana, range 1-8). La pHmetria e la pH impedenziometria esofagea delle 24 ore hanno mostrato livelli entro i limiti di normalità in 39/47 (83%) pazienti che hanno acconsentito ad effettuare l'esame.

**CONCLUSIONI:** I buoni risultati di questa serie di pazienti, dovuti a nostro avviso ad un'accurata aderenza ai principi tecnici dell'intervento chirurgico da noi descritti, conferma che l'intervento di Heller-Dor per via laparoscopica è il "gold standard" per il trattamento chirurgico dell'acalasia.

### References

1. Rosati R, Fumagalli U, Bonavina L, Segalin A, Montorsi M, Bona S, Peracchia A: *Laparoscopic approach to esophageal achalasia*. Am J Surg, 1995; 169:424-27.
2. Ancona E, Peracchia A, Zaninotto G, Rossi M, Bonavina L, Segalin A: *Heller laparoscopic cardiomyotomy with antireflux anterior fundoplication (Dor) in the treatment of esophageal achalasia*. Surg Endosc, 1993; 7:459-61.
3. Swanstrom LL, Pennings J: *Laparoscopic esophagomyotomy for achalasia*. Surg Endosc, 1995; 9:286-92.
4. Heller E: *Extramuköse cardioplastik beim chronischen cardiospasmus mit dilatation des oesophagus*. Mitt Grenzgeb Med Chir, 1913; 27:141.
5. Dor J, Humbert P, Dor V, Figarella J: *L'interêt de la technique de Nissen modifiée dans la prévention du reflux après cardiomyotomie extramucosale de Heller*. Mem Acad Chir (Paris), 1962; 88: 877-83.
6. Gerzic Z, Knezevic J, Milicevic M: *Results of transabdominal cardiomyotomy with Dor partial fundoplication in the management of achalasia*. In: Siewert JR, Holscher AH (eds) *Diseases of the esophagus*. Berlin: Springer Verlag, 1988; 970-74.
7. Desa L, Spencer J, McPherson S: *Surgery for achalasia cardia: The Dor operation*. Ann R Coll Surg Engl, 1990; 72:128-31.
8. Bonavina L, Nosadini A, Bardini R, Baessato M, Peracchia A: *Primary treatment of esophageal achalasia. Long-term results of myotomy and Dor fundoplication*. Arch Surg, 1992; 127:222-26.
9. Rosati R, Fumagalli U, Bona S, Chella B, and Peracchia A: *A special instrument to do a safe and effective esophageal myotomy through laparoscopy*. Surg Laparosc Endosc 1996; 6:385-87.
10. Csendes A, Braghetto I, Mascaro J, Henriquez A: *Late subjective and objective evaluation of the results of esophagomyotomy in 100 patients with achalasia of the esophagus*. Surgery, 1988; 104:469-75.
11. Peracchia A, Bonavina L, Nosadini A, Baessato M, Bardini R: *Management of recurrent symptoms after esophagomyotomy for achalasia*. Dis Esoph, 1990; 3:25-28.

12. Sugarbaker DJ, Kearney DJ, Richard WG: *Primary motor disorders*. In: Griffith Pearson F, Deslauriers J, Ginsberg RJ, Hiebert CA, McKneally MF, Urschel HC (eds): *Esophageal Surgery* New York : Churchill Livingstone, 1995; 425-42.
13. Del Genio G, Tolone S, Rossetti G, Bruscianno L, Pizza F, Del Genio F, Russo F, Di Martino M, Lucido F, Barra L, Maffettone V, Napolitano V, Del Genio A: *Objective assessment of gastroesophageal reflux after extended Heller myotomy and total fundoplication for achalasia with the use of 24-hour combined multichannel intraluminal impedance and pH monitoring (MII-pH)*. Dis Esophagus, 2008; 21(7):664-67.
14. Donahue PE, Schlesinger PK, Sluss KF: *Esophagocardiomyotomy: floppy Nissen fundoplication effectively treats achalasia without causing esophageal obstruction*. Surgery, 1994; 116:719-25.
15. Pandolfo N, Bortolotti M, Spigno L, Bozzano PL, Mattioli FP: *Manometric assessment of Heller-Dor operation for esophageal achalasia*. Hepatogastroenterology, 1996; 43:160-66.
16. Pellegrini C, Wetter LA, Patti M, Leichter R, Mussan G, Mori T, Bernstein G, Way LL: *Thoracoscopic esophagomyotomy*. Ann Surg, 1992; 216:291-99.
17. Raiser F, Perdakis G, Hinder R, Swannstrom LL, Filipi CJ, McBride PJ, Katada N, Neary PJ: *Heller myotomy via minimal-access surgery. An evaluation of antireflux procedures*. Arch Surg, 1996; 131: 593-98.
18. Rebecchi F, Giaccone C, Farinella E, Campaci R, Morino M. *Randomized controlled trial of laparoscopic Heller myotomy plus Dor fundoplication versus Nissen fundoplication for achalasia. Long-term results*. Ann Surg 2008; 248:1023-30.