

Laparoscopic deroofing in large hepatic cyst with alcohol sclerotherapy.

Analysis of three cases



Ann Ital Chir, 2022 93, 2: 224-228

pii: S0003469X22037095

Online ahead of print Jan. 28

free reading: www.annitalchir.com

Giulia Valeria Calabrese*, Matthew Waku**, Francesca Mazzarulli**, Decio Di Nuzzo****, Franco Ciarelli**, Alessandro Bennato**, Felice Mucilli***

*Resident Doctor in General Surgery, University "Gabriele D'Annunzio", Chieti, Pescara, Italy

**Department of General Surgery "S. Massimo" Hospital, Penne, Pescara, Italy

***Department of General and Thoracic Surgery, "SS Annunziata" Hospital, Chieti, Italy

****Department of Medical, Oral and Biotechnological Sciences, University "Gabriele D'Annunzio", Chieti, Pescara, Italy

Laparoscopic deroofing in large hepatic cyst with alcohol sclerotherapy. Analysis of three cases

Hepatic cysts have become increasingly frequent findings thanks to the improvement in diagnostic investigations. Distinction has to be made between congenital hepatic cysts (like liver cyst, PLCD) and acquired forms (such as a parasitic cyst and a cyst occurring as part of a neoplastic process) (1). When a simple hepatic cyst becomes symptomatic, when its size is > 4 cm or when there is some radiological suspicion of malignancy (thick wall, peripheral enhancement on CT/MRI) surgical management is indicated and relies on a variety of techniques (2). Presently the two most common techniques are percutaneous aspiration with sclerotherapy and laparoscopic fenestration. The use of laparoscopic approach has achieved, in the last years, some great results, for it shortens hospital stay, involves minimal invasiveness and offers low recurrence rate. We report three cases of symptomatic hepatic cysts successfully treated by using laparoscopic procedure.

KEY WORDS: Laparoscopic deroofing, Sclerotherapy, Simple hepatic cysts

Introduction

Over the last decade, the approach to general surgical diseases, especially in abdominal pathologies, has developed and diversified. Radiological images play a pivotal role in diagnostic procedures. For this reason the occasional findings of hepatic cysts has become more frequent, in the imaging techniques using ultrasound and CT scans, and their best treatment a salient point of discussion³. As we know from the literature hepatic cysts are divided into congenital and acquired; in the congenital form, the most frequent are simple cysts and

PLCD (polycystic liver disease), while the acquired type include both infectious (from parasites or abscesses) and non-infectious cysts (of a neoplastic nature or false cysts)⁴. In industrialized countries, simple cysts are the most common, in about 2,5-5% of the population. In most cases, they are asymptomatic and are the result of occasional findings during other radiological investigations; only 15% are accompanied by symptoms, mainly in cysts > 4 cm in size and located in the right lobe⁵. Simple cysts are generally solitary, more than one cyst may be present even in the absence of polycystic liver disease⁴. Asymptomatic cysts do not require treatment and those > 4cm in size should be monitored with serial imaging over time. Large cysts can become symptomatic as a result of their bulging effect, rupture or infection. The choice of their treatment is based on the position, size and type, and in any case the neoplastic pathology must always be excluded. For this reason, as Maruyama said at the end of his twelve-year experience, the laparoscopic surgical treatment seems to be the most reliable in terms of resolution and diagnostic efficacy compared to percutaneous drainage⁵.

Pervenuto in Redazione Settembre 2021. Accettato per la pubblicazione Ottobre 2021

Correspondence to: Giulia Valeria Calabrese, Resident Doctor in General Surgery, University Gabriele D'Annunzio Chieti, Pescara, SS Annunziata Hospital, Chieti, Italy (e-mail: giuliavaleria92@gmail.com)

ABBREVIATION

PLCD: polycystic liver disease
 CT: computer tomography
 MRI: Magnetic resonance imaging
 GCS: Glasgow coma score
 WBC: white blood cell

Materials and Methods

Among the cases encountered within our surgical experience at the Surgical Unit of S. Massimo Hospital, Penne (IT), we refer about three cases that occurred between 2020 and 2021. All three were females with an average age of 67.7 years, diagnosed with liver cyst > 4 cm in the right liver lobe. Clear symptoms only related to the presence of the cyst are reported in two patients while in the third case the symptoms seemed to be associated also with biliary pathologies. The operative procedure used was laparoscopic deroofing preceded in two cases by alcohol sclerotherapy. The mean operative time was 138 minutes. Subsequent histological diagnosis confirmed the benign nature of all cysts.

CASE N. 1

86 year old woman admitted to our surgical Unit because of high fever > 38°, numerous episodes of vomiting, right lung consolidation associated with bilateral pleural effusion, a strongly reduced GCS 8/15, WBC: 19.000, PCR: 150 subjected to antibiotic therapy for about 12 days . Abdomen CT scan shows: multiple hepatic cysts of which the largest one measured 12 x 15 cm occupying almost the entire right hepatic lobe (Fig. 1).

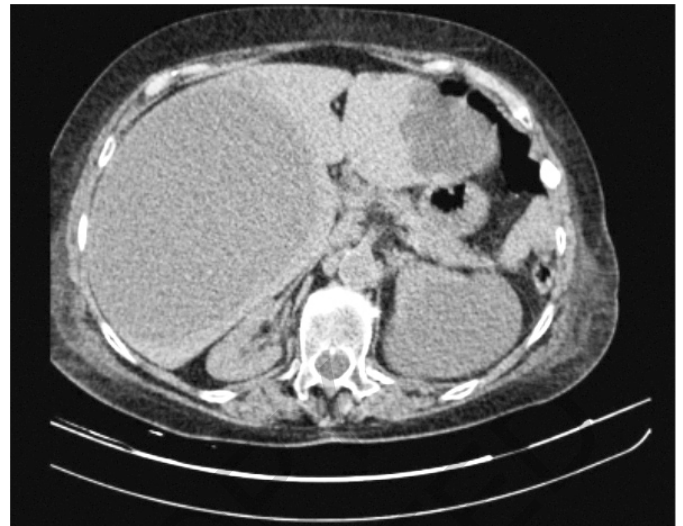

Fig. 1: Abdomen CT scan case 1.

Radiological, laboratory and clinical data suggested the cyst may have turned to an abscess.

A pyogenic liver abscess is a potentially lethal disease. The main therapy is the intravenous administration of antimicrobial drugs. When the disease resists for many weeks despite treatment or the abscess is bigger than 5cm, then a drainage is required. Drainage can be done via percutaneous needle aspiration, percutaneous catheter, open or laparoscopic surgical approach.

In our patient the procedure of choice was the laparoscopic deroofing to avoid a possible aspiration failure that could lead to uncontrolled infection spread considering that the abscess was large in size. Initial aspiration of 2000 cc of purulent material confirmed the presence of an abscess and for this reason it was decided to proceed directly with deroofing alone without previous sclerotherapy with alcohol. The patient's hospitalization lasted for 20 days, an unusual duration of time, but accord-

TABLE I

	Case 1	Case 2	Case 3
Age	86 Years	52 Years	65 Years
Size And Location	12 x 15 cm, In The Right Epatic Lobe	4,7 cm, VI Epatic Segment	6,5 x 12 cm, IV Epatic Segment
Symptoms	Sepsis (Fever, Vomiting, Reduction Of Gcs)	Colic Right Abdominal Pain.	Abdominal Discomfort, Right Abdominal Pain.
Operativeprocedure	Laparoscopic Deroofing	Laparoscopic Deroofing + Ethanol Sclerotherapy and Vls Colectectomy	Laparoscopic Deroofing + Ethanol Sclerotherapy
Hospital Stay	20 Days	3 Days	2 Days
Operative Time	125 Min	160 Min	130 Min
Complications	Defedation Caused By Sepsis	None	None
Plcd Disease	None	None	None
Post Operativemalignancy	None	None	None

ing to the septic state, the age and the important general physical and cognitive deficit. However, thanks to the administration of antibiotic therapy, parenteral infusions and electrolytic rebalance, the patient fully recovered from her initial clinical condition.

CASE N. 2

52 year old woman previously subjected to right hemicolectomy for Crohn's disease admitted because of colic pain probably of biliary origin. Radiological examinations confirmed the presence of a distended gallbladder with biliary sludge and also the presence of a large simple cyst, measuring 4,7 cm in diameter, located in the VI hepatic segment (Fig. 2). We cannot say with certainty that the patient's symptoms related to the gallbladder pathology could exclude the simple hepatic cyst from present or future symptoms. For this reason, since it was a cyst > 4 cm, it was considered appropriate to proceed with its removal in the same surgical time. Laparoscopic cholecystectomy was performed combined with deroofing of the cyst preceded by sclerotherapy with ethanol.

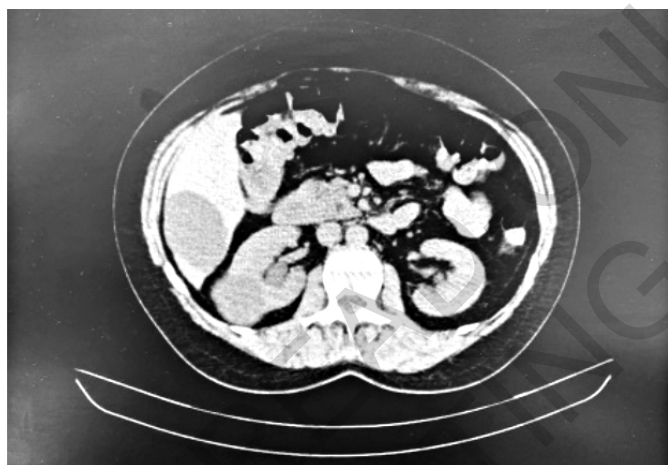


Fig. 2: Abdomen CT scan case 2.



Fig. 3: Injection of anhydrous alcohol.

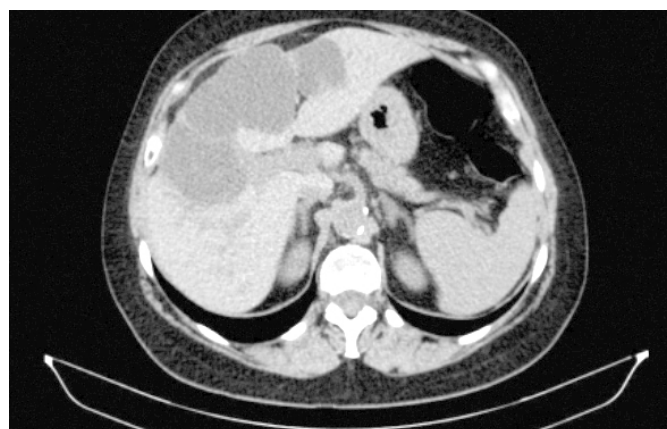

Fig. 4: Abdomen CT scan case 3.

Surgery included cyst wall puncture by using sand balloon catheter, aspiration, and injection of anhydrous alcohol using a volume equivalent to 10% of the capacity of the cyst (Fig. 3). Ten minutes after the injection, ethanol was removed, followed by deroofing using energy device.

CASE N. 3

65 year old woman previously subjected to three fenestrations for hepatic cysts. Patient was admitted because of recurrent pain in the right upper quadrant, bloating and abdominal distention frequently after eating. Abdomen CT scan reveals the presence of a large cyst in the IV hepatic segment measuring 6,5 x 12cm (Fig. 4).

Treatment of choice was laparoscopic deroofing preceded by sclerotherapy with ethanol. (same procedure previously explained). Patient was discharged one day after the surgical procedure in good general condition without any complication.

Discussion

The frequency of hepatic cysts is unknown because most of them do not cause symptoms but they are generally estimated to occur in 5% of the population⁶. No more than 10% - 15% of these patients have symptoms that lead to clinical attention. Simple non-parasitic hepatic cysts are congenital and are believed to be triggered by chromosome 16 arising as an aberration of bile duct development in the uterus cuboidal epithelium lining. The development has a possible aetiological connection to the presence of oestrogens due to their increase among women especially between 40–60 years of age. Liver cysts are usually found in the right liver (83%)⁷. Our patients were within these groups. The location of the cyst and its size usually determine the symptoms.

Generally, the hepatic cyst causes no symptoms and may be found incidentally at laparotomy or during abdomi-

nal imaging. However, large cysts may be responsible for abdominal lump, palpable mass, right upper quadrant pain (from stretching of hepatic capsule) and the large size increases the likelihood of infection. Compression of adjacent structures may result in the following clinical features: compression of the inferior vena cava resulting in lower extremity oedema, portal vein resulting in portal hypertension, and biliary tree resulting in jaundice⁸. In summary, we present three cases with large, symptomatic simple hepatic cyst. The usual standard of care for patients with simple hepatic cysts is observation but larger symptomatic cysts may require surgical treatment. As we learned from literature, laparoscopic deroofing and percutaneous aspiration, followed by sclerosis, are both reasonable approaches for the majority of symptomatic simple liver cysts⁹. Whereas sclerosis may be less invasive and associated with lower rates of complications, laparoscopy is effective and provides the opportunity to directly examine the cavity of the cyst to rule out pathologies other than a simple hepatic cyst. As recalled by Mazza in his review, it is important to rule out biliary communication before sclerotherapy as irreversible sclerosing cholangitis has been reported an important complication. The presence of cysto-biliary communication may be established by endoscopic retrograde cholangiography or aspiration of bile-stained cystic fluid and is often treated by open cystojejunostomy, although the cysto-biliary communication may be closed laparoscopically¹⁰. The treatment choice derives from multiple considerations: aspiration alone is associated with an high rates of recurrence and may increase the infection rate especially in the larger cyst, and there isn't the possibility to make an histological exam of the cyst. Despite laparoscopic approach may have a higher complication rate than percutaneous drainage but the laparoscopic procedure currently offers a more definitive resolution with a relapse rate that is close to 0%. Moreover, as Regev mentions in his experience, it is the only approach that can provide with certainty the histological nature of the cyst¹¹.

Conclusion

Laparoscopic deroofing of simple hepatic cysts is an easy, reproducible and efficient method with minimal surgical trauma and should represent the standard therapeutic approach for symptomatic cystic liver disease. The limits of minimally invasive approach are the posterior or deep localizations.

Laparoscopic deroofing has also been applied in cases of PCLD, particular in cases of few large cysts located in the anterior segments with less recurrence rates of the Percutaneous aspiration.

Finally the possibility of providing a histological definition of the cyst after laparoscopic approach, certainly represents an important point in favor of this technique.

Riassunto

Le cisti epatiche semplici sono congenite con una prevalenza del 2,5%-4,25% nella popolazione. L'imaging, sia mediante ecografia, TC o RM, è di solito accurato nel distinguere le cisti semplici da altre eziologie, comprese le cisti parassitarie, neoplastiche, legate al dotto biliare e traumatiche. Le cisti epatiche semplici sono generalmente asintomatiche, quelle sintomatiche sono prevalentemente grandi (> 4 cm), più frequenti sul lato destro del fegato e più comuni nelle donne e nei pazienti più anziani. La maggioranza delle cisti epatiche semplici non richiede alcun trattamento o follow-up, tuttavia le grandi cisti epatiche > 4cm a causa dell'effetto massa, della loro potenziale rottura o della loro infezione possono causare importanti complicanze. Per questi motivi è consigliato il loro trattamento una volta individuato con certezza che siano causa della sintomatologia del paziente o che le loro dimensioni possano portare a complicanze nel tempo. I trattamenti di scelta per la rimozione delle cisti epatiche semplici possono essere mini invasivi come l'aspirazione percutanea, che tuttavia presenta un alto tasso di recidiva, oppure sempre più utilizzato è il deroofing laparoscopico combinato alla scleroterapia con alcol. All'interno dell'articolo abbiamo scelto di analizzare tre casi clinici intercorsi nel nostro reparto di Chirurgia Generale tra il 2020 e il 2021, motivando il nostro approccio chirurgico e analizzandone i pro e i contro.

References

1. Moorthy K, Mihssin N, Houghton PW: *The management of simple hepatic cysts: Sclerotherapy or laparoscopic fenestration*. Ann R Coll Surg Engl, 2001; 83:409-14. PMID:PMC2503687
2. Zacherl J, Scheuba C, Imhof M, Jakerez R, Fugger R: *Long-term results after laparoscopic unroofing of solitary symptomatic congenital liver cysts*. Surg Endosc, 2000; 14: 59-72. DOI :10.1007/s004649900012. PubMed:10653238
3. Tartaglia N, Di Lascia A, Cianci P, Vovola F, Pacilli M: *Surgical management of non-parasitic hepatic cysts. A single center experience*. Ann Ital Chir, 2019.
4. Tagaya N, Nemoto T, Kubota K: *Long-term results of laparoscopic unroofing of symptomatic solitary nonparasitic hepatic cysts*. Surg Laparosc Endosc Percutan Tech, 2003; 13:76-79. DOI:10.1097/00129689-200304000-00003
5. Brozzetti S, Miccini S, Bononi M, Al Mansour M: *Treatment of congenital liver cysts. A surgical technique tailored through a 35-years experience*. Ann Ital Chir, 2013.
6. Blonski WC, Campbell MS, Faust T, Metz DC: *Successfull aspiration and ethanol sclerosis of a karge, symptomatic, simple liver cyst*. World J Gastroenterol. 2006; 12: 2949-954. DOI:10.3748/wjg.v12.i18.2949
7. Maruyama Y, Okuda K, Ogata T, Yasunaga M: *Perioperative challenges and surgical treatment of large simple and infectious liver*

- cyst. A 12 year experience.* 2013; 8(10): 765-67. DOI: 10.1371/journal.pone.0076537
8. Tan L, Zhou HJ, Hartman M, Ganphati IS, Madhavan K: *Laparoscopic drainage of cryptogenic liver abscess.* Surg Endosc Other Interv Tech. 2013; 75(7): 577-80. DOI:10.1007/s00464-013-2910-y
9. Gloor B, Ly Q, Candinas D: *Role of laparoscopy in hepatic cyst surgery.* Digestive Surgery, 2002; 19(6):494-99. DOI:10.1159/000067603
10. Stanescu CA, Paduraru DN, Crimbei C: *The laparoscopic management of simple hepatic cysts.* Journal of Medicine and Life, 2015; 8(3):342-45. PMID:PMC4556917
11. Flamingo P, Tedeschi U, Veroux M: *Laparoscopic treatment of simple hepatic cysts and polycystic liver disease.* Surg Endosc, 2003; 17:623-26. DOI: 10.1007/s00464-002-9088-z
12. Mazza O, Fernandez D, Pekol J, Plaffen G: *Management of nonparasitic hepatic cysts.* J Am Coll Surg, 2009; 209:733-39. DOI:10.1016/j.jamcollsurg.2009.09.006. PubMed: 19959042
13. Regev A, Reddy KR, Berho M, Moline EG: *Large cystic lesions of the liver in adults: A 15- year experience in a tertiary center.* J Am Coll Surg, 2001; 143:33-45. DOI:10.1016/s1072-7515(01)00865-1

READ-ONLY COPY
PRINTING PROHIBITED