

# Obstructing left sided colorectal cancer.

## A retrospective single Center study.



Ann Ital Chir, 2019 90, 2: 121-126

pii: S0003469X19029178

Epub Ahead of Print - December 7

free reading: [www.annitalchir.com](http://www.annitalchir.com)

Michele Danzi\*, Luciano Grimaldi\*, Michele De Capua\*\*, Nicola Tammaro\*,  
Roberta Danzi\*\*\*, Luigi Sivero\*\*

University "Federico II" Naples, Italy

\*Department of Specialized Surgery, Division of General and Emergency Surgery

\*\*Department of Gastroenterology, Endocrinology, Endoscopic Surgery

\*\*\*Department of Diagnostic Imaging and Radiotherapy

### Obstructing left sided colorectal cancer. A retrospective single Center study.

**BACKGROUND:** *In recent years, with population aging, there has been an increased number of colorectal cancer cases with severe occlusion symptoms. About 75% of obstructions due to malignant colorectal cancer (10-30%) occur distal to splenic flexure.*

**METHODS:** *The authors evaluated the best surgical therapeutic strategy to be used in cases of left-sided colorectal carcinoma in patients over 65 years old, especially considering the emergency condition, age of patients and efficacy in terms of postoperative morbidity, mortality and 5 years survival rate.*

**RESULTS:** *The management of left-sided obstructing colorectal carcinoma is controversial. Hartmann's procedure is the best therapeutic choice in elderly patients. However, resection with intraoperative colonic wash-out and primary anastomosis has favorable outcome in low risk patients.*

**CONCLUSIONS:** *A review of the literature reveals that primary resection and anastomosis for left-sided obstructing CRC is the correct therapeutic strategy in low risk patients with localized, resectable carcinoma, without peritonitis; Hartmann's procedure should be adopted in doubtful cases and in high risk patients.*

**KEYWORDS:** Colorectal left-sided cancer, Emergency surgery, Intestinal obstructions in elderly

### Background

The most common causes of mechanical bowel obstruction are: malignant tumors, volvulus, diverticulitis and fecaloma; colorectal cancers represent the 10%-30% of bowel obstructions. In the 75% of cases the obstruction occur distal to splenic flexure of the colon <sup>1</sup>. In recent

years, with population aging, there has been an increased number of colorectal cancer cases with severe occlusion symptom <sup>2</sup>. The post-operative mortality rate is significantly greater in the elderly than in younger patients <sup>3</sup>. The best surgical strategy for the treatment of left-sided obstructing colorectal carcinoma and the extension of the bowel resection are controversial.

Dispute also concerns the opportunity to perform primary resection and anastomosis in emergency condition considering the age of the patients, colonic gaseous distension and fecal load <sup>4,5</sup>.

In our retrospective study, we evaluate the surgical therapeutic strategies adopted for the treatment of left-sided obstructing CRC in patients over 65 years old and efficacy in terms of postoperative mortality, morbidity and 5 years survival rate.

*Pervenuto in Redazione Luglio 2018. Accettato per la pubblicazione Ottobre 2018*

*Correspondence to: Danzi Michele, MD, Department of Specialized Surgery, Division of General and Emergency Surgery, "Federico II" University, ed. 5, via S. Pansini 5, 80131, Naples - Italy. (e-mail: [michele.danzi@unina.it](mailto:michele.danzi@unina.it))*

## ABBREVIATIONS

CRC: Colorectal Cancer  
 PT: Patient  
 CT: Computerised tomography  
 IMA: Acute myocardial infarction  
 ASA: American Society of Anaesthesiologists

## Methods

## PATIENTS

During the 15 years between January 1998 to October 2013, 557 consecutive patients underwent surgery for primary CRC in our Hospital; of these 295 males and 262 females. The mean age was 74,3 years (range of 36 to 92 years). 362 patients were over 65 years old. Sixty-five of these patients underwent emergency surgery for intestinal obstruction (18%) and only 51 (78%) had a left-sided obstructing CRC (Fig. 1).

Inclusion criteria were: left-sided obstructing CRC; emergency operation within 24-36 h; no perforations, no peritonitis.

These patients had clinical features of intestinal obstruction as abdominal pain and distension, nausea or vomiting. Abdomino-pelvic CT with and without intravenous contrast injection, abdominal plain film radiography, also with Gastrografin, were performed to confirm the diag-

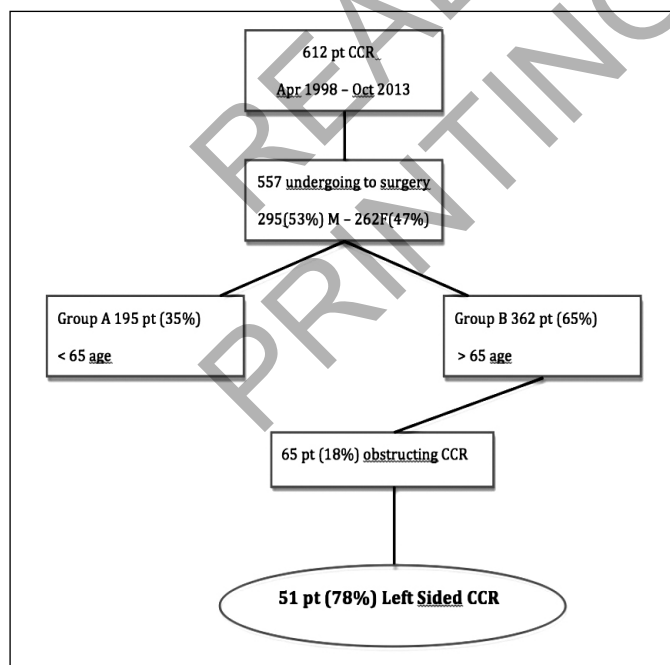


Fig. 1: Patients and Groups.

nosis, to provide the most accurate informations about the site of the obstruction, evidence of locoregional extension to lymphnodes and to adjacent organs and metastasis to the liver and peritoneum. Furthermore it shows signs of cecal dilatation (with diameter measurement), the presence of synchronous lesions before the site of obstruction.

Colonoscopy was also performed whenever possible. It may offer direct visualization of the obstructive lesion and may help in ruling out other causes such as fecaloma, volvulus, diverticular disease. Preoperative management included: fluid replacement, correction of electrolyte disturbances, nasogastric decompression, medical consultations (depending on the comorbidities such as cardiorespiratory and metabolic diseases, renal insufficiency) and intravenous prophylactic antibiotics (cefalosporins and metronidazole). Perioperative prophylaxis routinely included subcutaneous heparin administration according to the current literature<sup>6</sup>. The collected data were studied through 2x2 contingency tables and statistics of  $\chi^2$ ; p values <0.05 were considered statistically significant.

## Results

Types of surgery performed were:

- 27 Hartmann's procedures, in 16 cases reanastomosis was later performed;
- 5 primary resection and anastomosis with proximal protective colostomy;
- 6 primary resection and anastomosis with intraoperative colonic wash-out conducted introducing a Foley catheter (20-22 Fr) through the appendix or a small enterotomy. A protective ileostomy was also performed;
- 8 primary resection and anastomosis with intraoperative colonic wash-out without protective stoma;
- 1 subtotal colectomy with ileosigmoid anastomosis (Fig. 2);
- 4 decompressive colostomies.

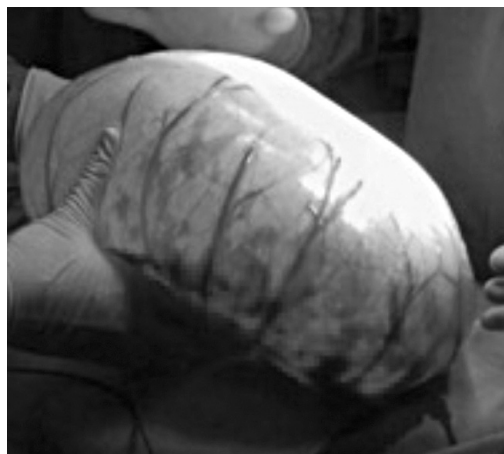

Fig. 2: Bowel Obstruction. Considerable transverse colon dilatation due to obstructing sigmoid cancer.

Among 47 (92%)/51 patients having primary resection of the left-sided cancer, 20 (42%)/47 had primary anastomosis and 11 (55%)/20 of these, required proximal protective stoma due fragile colonic wall.

The overall primary resection and anastomosis rate in left-sided cancer was 39%.

Among those patients who had primary anastomosis, 19 (95%)/20 had a partial resection with irrigation or manual decompression. Only one had sub-total colectomy with ileo-sigmoid anastomosis without colonic irrigation. In this patient, sub-total colectomy was performed because of synchronous lesion of the right colon.

All anastomosis were performed with mechanical staplers: 22 termino-terminal anastomosis with circular stapler and only 4 latero-lateral anastomosis with linear stapler.

### **Post-operative Morbidity and Mortality**

We reported 36 postoperative complications: 16 (44%) surgical and 20 (56%) medical complications.

An anastomotic leakage occurred in 3 (15%)/20 patients: two of the 8 who underwent primary resection and anastomosis without protective stoma and one patient who underwent primary resection and anastomosis with protective ileostomy.

A stoma complication occurred in 3 (7%)/42: two colostomies with partial necrosis and one with stenosis. Wound infections, abdominal abscesses and bleeding were, respectively, the 13%, 3% and 2% of surgical complications.

The postoperative mortality rate was 12% (6/51). The causes of the death were: anastomotic leakage in two patients who underwent primary resection and anastomosis, intrabdominal sepsis in one patient, pneumonia in two patients and myocardial infarction in one patient.

The overall survival rate after 5 years was 29% (15/51).

### **Discussion and Conclusions**

With an aging population, recent years it has been recorded an increased number of CRC, who presented clinical features of intestinal obstruction in the 10-20% of cases, 75% occurring distal to splenic flexure <sup>1</sup>.

The perioperative mortality rate in patients with an obstructing CRC is higher than in elective procedure (19,9% vs 5,1%) <sup>3,7</sup>.

These data are related to the age of the patients, their general conditions, ASA score, eventual comorbidities, metabolic alterations from the occlusive condition, the more advanced stage of the cancer. Emergency surgery represents an independent risk factor of mortality <sup>8,9</sup>.

The gold standard for complicated obstructing right-sided colonic carcinoma is the right hemicolectomy with primary anastomosis, because, as suggested by the litera-

ture, complication and mortality rates in these cases are similar to those of elective surgery <sup>10</sup>.

However, there is no unanimity for left-sided obstructing colorectal carcinoma, above all in elderly patients, which are currently the most frequently encountered.

Hartmann's resection is considered, as in our study reported, the best procedure in the elderly, because it is able both to treat cancer in terms of oncological radicality (R0) and to reduce the perioperative mortality and morbidity <sup>11,12</sup>.

Hartmann's procedure is associated with a longer hospital stay and more complications related to the colostomy which occurred in 10% of the patients in different series <sup>13,14</sup>.

However, Hartmann's reversal is associated with significant mortality and morbidity in the elderly <sup>15</sup>.

A recent German study found that segmental colectomy without immediate restoration of continuity was the most commonly used procedure in high risk patients <sup>11</sup>.

In 27 elderly patients of our series, Hartmann's was a safe procedure without mortality and with very low morbidity. Intestinal continuity was later performed in 16 patients with elective procedure when patient's condition improved (Hartmann reversal rate of 59%).

In the 20% of the patients reanastomosis can't be performed due to systemic comorbidities and/or because the patients refuse the treatment <sup>10,16</sup>.

Primary resection and anastomosis with intraoperative colonic wash-out seems to be the best surgical operative choice for low risk patients.

This contrasts with our experience where two deaths occurred for anastomotic leaks in that group of patients.

In recent years, the direct anastomosis is performed both after resection and after subtotal colectomy or total colectomy <sup>17</sup>.

Direct anastomosis can be performed to treat obstructions that occur chronically more safely than acute cases, where there is a higher risk of intestinal ischemic suffering and prevalence of anaerobic bacterial flora (Clostrides) <sup>18</sup>.

From an analysis of the literature it is unclear what type of one-stage procedure is the best one to adopt <sup>19</sup>, but the advantages of this technique are common:

- reduced hospital stay;
- whole resection of the prestenotic dilated colon, usually poor vascularized and with a high fecal load, eventually followed by a safer ileosigmoid or ileorectal anastomosis;
- easier closure of the abdominal wall, without dilated intestinal tracts, and a lower incidence of incisional hernia;
- possibility to remove synchronous tumors (3% of cases of adenomas or carcinomas).

However, it should be emphasized that subtotal colectomy is indicated in presence of a reasonable risk, for potentially resectable tumor, in case of massive bowel dilatation with signs of initial or impending necrosis or

caecal diastasis, for suspected radiological or intraoperative synchronous tumors.

In our study, we performed only one subtotal colectomy with latero-lateral ileo-sigmoid anastomosis in the presence of a right colon synchronous tumor, because we believe, according to the literature <sup>11</sup>, that elderly patients with voluminous or locally advanced neoplasia, who underwent an emergency surgical treatment, would have a too high post-operative morbidity rate in terms of diarrhea, hyponatremia and dehydration.

When we performed a colo-colonic anastomosis, the proximal colon should be emptied of the fecal load and gas. This condition can be reached with two procedures: intraoperative colon irrigation and/or manual decompression. In our study, we performed a protective stoma in 11/20 patients undergone to primary anastomosis. As well known a protective stoma does not prevent anastomotic leakage but limits the severity of the peritonitis <sup>11</sup>.

We performed 5 protective colostomies and 6 protective ileostomy. Ileostomy is easier to perform, avoids involvement of colonic vascularization and is associated with fewer complications than colostomy closure <sup>8</sup>.

We reported, in our series, 3 stoma complications, 2 of which in the group of primary anastomosis and protective colostomy. No morbidity was associated with ileostomy closure. Decompressive colostomy proves to be useful only in case of advanced neoplasia or when general conditions of the patients are dramatic <sup>5,20</sup>.

In our experience, we performed 4 decompressive colostomies, two for advanced neoplasia and two for the very high operative risks (ASA IV). Only one patient underwent tumor resection 7-10 days later, followed by resection – anastomosis and subsequently stoma closure (“three stages technique”); this procedure has high mortality and morbidity rates associated with low long term survival rate, therefore it’s rarely performed and only in very high risk patients <sup>21</sup>.

It would be interesting to evaluate the efficacy and role of endoscopy by using self-expanding stents, purely for decompressive purposes, to stabilize the patient and performing an elective resection 5-7 days later <sup>22,23</sup>. This could prevent or at least reduce the use of decompressive stoma with significant cost, morbidity and mortality savings.

This procedure, not in expert centers, has been associated with several complications such as perforation (4%), bleeding (5%) and stent migration (5-10%) <sup>24</sup>.

From a literature review, in case of obstructing left-sided CRC, primary resection and anastomosis are indicated in low-risk patients with localized, resectable tumor.

In doubtful cases, elderly and high risk patients, Hartmann’s procedure should be adopted <sup>11,25</sup>.

## Riassunto

Negli ultimi anni, con l’invecchiamento della popolazione, c’è stato un aumento del numero di casi di tumo-

re del colon-retto con sintomi gravi di occlusione. Circa il 75% delle ostruzioni dovute a tumore maligno del colon-retto (10-30%) si verificano distalmente alla flessura splenica.

**METODI:** Gli autori hanno valutato la migliore strategia a chirurgica terapeutica da utilizzare nei casi di carcinoma colo-rettale sinistro in pazienti di età superiore a 65 anni, soprattutto considerando la condizione di emergenza, l’età dei pazienti e l’efficacia in termini di morbilità postoperatoria, mortalità e sopravvivenza a 5 anni di vita.

**RISULTATI:** La gestione del carcinoma colo-rettale ostruttivo del lato sinistro è controversa. La procedura di Hartmann è la migliore scelta terapeutica nei pazienti anziani. Tuttavia, la resezione con wash-out intraoperatorio del colon e anastomosi primaria ha esito favorevole nei pazienti a basso rischio.

**CONCLUSIONI:** Una revisione della letteratura rivela che la resezione primaria e l’anastomosi, per carcinoma colo-rettale ostruttivo sul lato sinistro, sono la strategia terapeutica corretta nei pazienti a basso rischio con carcinoma localizzato e resecabile, senza peritonite. La procedura di Hartmann dovrebbe essere adottata nei casi dubbi e nei pazienti ad alto rischio.

## References

1. Griffith RS: *Preoperative evaluation. Medical obstacles to surgery. Cancer.* 1992; 70(5 Suppl):1333-41.
2. Umpleby HC, Williamson RC: *Survival in acute obstructing colorectal carcinoma.* Dis Colon Rectum, 1984; 27:299-304.
3. Carraro PG, Segala M, Cesana BM, Tiberio G: *Obstructing colonic cancer: failure and survival patterns over a ten-year follow-up after one-stage curative surgery.* Dis Colon Rectum, 2001; 44(2):243-50.
4. Arnaud JP, Bergamaschi R: *Emergency subtotal/total colectomy with anastomosis for acutely obstructed carcinoma of the left colon.* Dis Colon Rectum, 1994; 37(7):685-88.
5. Krstic S, Resanovic V, Alempijevic T, Resanovic A, Sijacki A, Djukic V, Loncar Z, Karamarkovic A: *Hartmann’s procedure vs loop colostomy in the treatment of obstructive rectosigmoid cancer.* World J Emerg Surg, 2014; 9(1):52. doi: 10.1186/1749-7922-9-52. eCollection 2014.
6. Di Minno MN, Milone M, Mastronardi P, Ambrosino A, Di Minno A, Parolari A, Tremoli E, Prisco D: *Perioperative handling of antiplatelet drugs.* Current Drug Targets, 2013; 14:880-88.
7. Corsale I, Foglia E, Mandato M, Rigutini M: *Occlusione intestinale da neoplasia maligna del colon: Strategia chirurgica.* G. Chir, 2003; 24(3):86-91.
8. Gainant A: *Emergency management of acute colonic cancer obstruction.* Journal of Visceral Surgery, 149:e3-e10.
9. Alves A, Panis Y, Mathieu P, et al.: *Postoperative mortality and morbidity in French patients undergoing colorectal surgery: Results of a prospective multicenter study.* Arch Surg, 2005; 140(3):278-83.
10. Ansaloni L, Andersson RE, Bazzoli F, Catena F, Cennamo V,

- Di Saverio S, Fuccio L, Jeekel H, Leppäniemi A, Moore E, Pinna AD, Pisano M, Repici A, Sugarbaker PH, Tuech JJ: *Guidelines in the management of obstructing cancer of the left colon: Consensus conference of the world society of emergency surgery (WSES) and peritoneum and surgery (PnS) society*. World J Emerg Surg, 2010; 5:29. doi: 10.1186/1749-7922-5-29.
11. Kube R, Granowski D, Stübs P, Mroczkowski P, Ptok H, Schmidt U, Gastinger I, Lippert H; Study group Qualitätssicherung Kolon/Rektum-Karzinome (Primärtumor): (*Quality assurance in primary colorectal carcinoma*). *Surgical practices for malignant left colonic obstruction in Germany*. Eur J Surg Oncol, 2010; 36(1):65-71. doi: 10.1016/j.ejso.2009.08.005. Epub 2009 Sep 10.
12. David GG, Al-Sarira AA, Willmott S, Cade D, Corless DJ, Slavin JP: *Use of Hartmann's procedure in England*. Colorectal Dis, 2009; 11(3):308-12. doi: 10.1111/j.1463-1318.2008.01586.x. Epub 2008 May 29.
13. Villar JM, Martinez AP, Villegas MT, Muffak K, Mansilla A, Garrote D, Ferron JA: *Surgical options for malignant left-sided colonic obstruction*. Surg Today, 2005; 35(4):275-81.
14. Poon RT, Law WL, Chu KW, Wong J: *Emergency resection and primary anastomosis for left-sided obstructing colorectal carcinoma in the elderly*. Br J Surg, 1998; 85(11):1539-542.
15. Wong RW, Rappaport WD, Witzke DB, Putnam CW, Hunter GC: *Factors influencing the safety of colostomy closure in the elderly*. J Surg Res, 1994; 57(2):289-92.
16. Desai DC, Brennan EJ, Reilly JF, Smink RD: *The utility of the Hartmann procedure*. Am J Surg, 1998; 175:152-54.
17. Sasaki K, Kazama S, Sunami E, Tsuno NH, Nozawa H, Nagawa H, Kitayama J: *One-stage segmental colectomy and primary anastomosis after intraoperative colonic irrigation and total colonoscopy for patients with obstruction due to left-sided colorectal cancer*. Dis Colon Rectum, 2012; 55(1):72-8. doi: 10.1097/DCR.0b013e318239be5e.
18. Mirza NN, McCloud JM, Cheetham MJ: *Clostridium septicum sepsis and colorectal cancer. A reminder*. World J Surg Oncol, 2009; 7:73. doi: 10.1186/1477-7819-7-73.
19. Torralba JA, Robles R, Parrilla P, Lujan JA, Liron R, Piñero A, Fernandez JA: *Subtotal colectomy vs. intraoperative colonic irrigation in the management of obstructed left colon carcinoma*. Dis Colon Rectum, 1998; 41(1):18-22.
20. Sjo OH, Larsen S, Lunde OC, Nesbakken A: *Short term outcome after emergency and elective surgery for colon cancer*. Colorectal Dis, 2009; 11(7):733-49. doi: 10.1111/j.1463-1318.2008.01613.x. Epub 2008 Jul 9.
21. Lee YM1, Law WL, Chu KW, Poon RT: *Emergency surgery for obstructing colorectal cancers: A comparison between right-sided and left-sided lesions*. J Am Coll Surg, 2001; 192(6):719-25.
22. Zhang Y, Shi J, Shi B, Song CY, Xie WF, Chen YX: *Self-expanding metallic stent as a bridge to surgery versus emergency surgery for obstructive colorectal cancer: A meta-analysis*. Surg Endosc, 2012; 26(1):110-19. doi: 10.1007/s00464-011-1835-6. Epub 2011 Jul 26.
23. Alcántara M1, Serra-Aracil X, Falcó J, Mora L, Bombardó J, Navarro S: *Prospective, controlled, randomized study of intraoperative colonic lavage versus stent placement in obstructive left-sided colonic cancer*. World J Surg, 2011; 35(8):1904-910. doi: 10.1007/s00268-011-1139-y.
24. Sebastian S, Johnston S, Geoghegan T, Torreggiani W, Buckley M: *Pooled analysis of the efficacy and safety of self-expanding metal stenting in malignant colorectal obstruction*. Am J Gastroenterol, 2004; 99(10):2051-57.
25. Meyer F, Marusch F, Koch A, Meyer L, Führer S, Köckerling F, Lippert H, Gastinger I: German Study Group "Colorectal Carcinoma (Primary Tumor): *Emergency operation in carcinomas of the left colon: value of Hartmann's procedure*. Tech Coloproctol, 2004; 8(Suppl 1):s226-9.

## Commento e Commentary

PROF. NICOLA PICARDI

Già Ordinario di Chirurgia Generale

Si possono condividere le conclusioni degli Autori, precisando però che la procedura di Hartmann, suggerita per i pazienti veramente anziani e fragili, rappresenta una via senza ritorno, perché con estrema difficoltà questi pazienti vorranno affrontare un nuovo impegnativo intervento di ricostruzione, né tutti i chirurghi vorranno operare in queste condizioni. Si tratta quindi di una procedura da adottare come “salvavita” quando, effettivamente, le condizioni generali sconsigliano, un intervento di resezione in un tempo.

Bisogna anche considerare che l'intervento di Hartmann lascia il paziente in una condizione di menomazione psicologica e con difficoltà di autogestione, specie se si tratta di pazienti particolarmente deficitari.

I progressi della tecnica chirurgica, le possibilità offerte dalla tecnica di Dudley, l'uso di suturatrici meccaniche, le opportunità offerte dalla nutrizione artificiale, le variabili coperture antibiotiche, le tecniche avanzate di assistenza postoperatoria dovrebbero stimolare il chirurgo ad affrontare come una prima scelta l'intervento di resezione colica - eventualmente anche di limitata estensione - nei casi che non rappresentino una vera urgenza e ,quando sia possibile, una minima preparazione all'intervento, incoraggiando il paziente ad affrontare un rischio limitato, prospettando il vantaggio di un possibile totale recupero cenestesico e psicologico per gli anni di vita restanti.

Naturalmente gravi complicanze di tipo cardiocircolatorio e carenze dell'emuntorio renale, oltre ai casi di peritonite, fanno ritenere l'intervento di Hartmann la soluzione di prima scelta, con la consapevolezza però che con elevata probabilità non vi saranno interventi ricostruttivi nel prosieguo.

\* \* \*

*The Authors' conclusions can be shared, however, specifying that the Hartmann procedure, suggested for truly elderly and frail patients, represents a way without return, because with extreme difficulty these patients will face a new demanding reconstruction intervention, not all surgeons will want to operate under these conditions are in fact discouraging a resection intervention in one time.*

*We must also consider that the intervention of Hartmann leaves the patient in a condition of psychological impairment and with difficulty of self-management, especially if they are particularly deficitary.*

*Advances in surgical technique, the possibilities offered by the Dudley technique, the use of mechanical staplers, the opportunities offered by artificial nutrition, the variable antibiotic coverage the advanced postoperative care techniques should stimulate the surgeon to face as first choice the colic resection - possibly even of limited extension - in cases that don't represent a real urgency, and when a minimum preparation for intervention is possible, encouraging the patient to face a limited risk, proposing the advantage of a possible total coenesthetic and psychological recovery for the remaining years of life.*

*Naturally serious cardiovascular complications and defects of kidney emunctory, in addition to cases of peritonitis, suggest that the Hartmann's intervention is the first choice solution, with the awareness, however, that with probability there were no reconstructive interventions in the future.*